

# Ayurvedic Management of Idiopathic Thrombocytopenic Purpura in a 4-Year-Old Child: A Case Report

Klita Pereira, Renu Rathi

Department of Kaumarbhritya, Mahatma Gandhi Ayurved College, Hospital and Research Centre, Datta Meghe Institute of Higher Education and Research, Wardha, Maharashtra, India

## Abstract

Idiopathic thrombocytopenic purpura (ITP) is an autoimmune hematological disorder characterized by isolated thrombocytopenia, often presenting with mucocutaneous bleeding.<sup>[1,5]</sup> Conventional management includes corticosteroids, intravenous immunoglobulins, and immunosuppressive agents, which may cause adverse effects in pediatric populations.<sup>[5]</sup> Ayurveda describes bleeding disorders under *Raktapitta*, wherein *Pitta* vitiation leads to *Rakta Dhatu* derangement and vessel fragility.<sup>[3]</sup> This case report highlights the successful Ayurvedic management of a 4-year-old male child diagnosed with ITP, who presented with petechiae, gum bleeding, and severe thrombocytopenia (11,000/cmm). The treatment protocol included *Raktapitta Chikitsa*, *Rasayana*, and immune-modulatory Ayurvedic formulations, such as Plateup syrup, Kumar Kalyan Rasa, Suvarna Vasant Malti Rasa, and Arvindasava. Significant clinical improvement was observed within 4 weeks, with platelet counts normalizing to 1.98 lakh/cmm by the 2<sup>nd</sup> month and maintaining at 2.29 lakh/cmm at 3 months without relapse. This case suggests that Ayurvedic therapy may serve as a supportive and potentially beneficial approach in pediatric ITP. Controlled studies are needed to validate these findings.

**Key words:** Ayurveda, Idiopathic thrombocytopenic purpura, Pediatric idiopathic thrombocytopenic purpura, Platelet count, Raktapitta, Rasayana

## INTRODUCTION

Idiopathic thrombocytopenic purpura (ITP) is an autoimmune condition presenting with isolated thrombocytopenia (platelet count  $<100,000/\text{mm}^3$ ) in the absence of other underlying causes.<sup>[5]</sup> Pediatric ITP typically manifests acutely and may follow a viral infection or immunologic trigger. Clinical features include petechiae, purpura, mucosal bleeding, and easy bruising. The incidence of ITP in children is approximately 1.9–6.4/100,000/year.<sup>[5]</sup>

Ayurveda explains bleeding disorders under *Raktapitta*, where vitiated *Pitta* affects *Rakta Dhatu*, resulting in hemorrhagic manifestations.<sup>[1]</sup> Based on symptomatology and pathogenesis, ITP closely resembles *TiryakaRaktapitta*, characterized by bleeding from the skin due to *Rakta* and *Pitta* dushti.<sup>[3]</sup>

Ayurvedic treatment aims to:

- Pacify vitiated *Pitta*
- Purify *Rakta Dhatu*
- Strengthen vascular integrity (*Srotas*)
- Enhance immunity and hematopoiesis through *Rasayana Chikitsa*<sup>[4]</sup>

This case report documents the integrative Ayurvedic management of ITP in a young child, demonstrating significant improvement in platelet count and overall well-being.

### Address for correspondence:

Dr. Klita Pereira, Department of Kaumarbhritya, Mahatma Gandhi Ayurved College, Hospital and Research Centre, Datta Meghe Institute of Higher Education and Research, Wardha, Maharashtra, India. Phone: 9967902890. E-mail: klitapereira02@gmail.com

**Received:** 19-11-2025

**Revised:** 03-02-2026

**Accepted:** 18-02-2026

## CASE REPORT

### Case history

#### Patient information

A 4-year-old male child from Mumbai presented on November 17, 2021 with petechial rashes, bruising, and occasional gum bleeding for 10 days.

#### History of present illness

The child was previously healthy when his parents noticed reddish spots over the limbs and trunk, followed by mild gum bleeding during tooth brushing. There was no fever, joint pain, abdominal pain, history of trauma, or drug intake.

A complete blood count (CBC) revealed thrombocytopenia (33,000/cmm). He was provisionally diagnosed with ITP at the local hospital and received supportive treatment. A repeat CBC showed a further drop in platelet count to 11,000/cmm. Concerned about the decline and recurrence of symptoms, the parents sought Ayurvedic management.

#### Past medical and family history

- No history of similar illness
- Immunizations up to date
- No family history of hematological disorders.

### Clinical examination

#### General examination

- Appearance: Mild pallor, petechiae on limbs and trunk
- Vital signs: Stable
- No hepatosplenomegaly
- No lymphadenopathy.

#### Ashtavidha pariksha

- Nadi: Pitta-pradhana, Kapha-anubandha
- Mala and Mutra: Normal
- Jivha: Coated
- Shabda, Sparsha, Drik: Normal
- Akriti: Madhyama.

#### Dashavidha pariksha

- Dushya: Rakta
- Desha: Sadharana
- Bala: Madhyama
- Kala: Sharad Ritu
- Agni: Mandagni
- Prakriti: Pitta-Kapha
- Vaya: Bala (child)
- Satva: Madhyama
- Satmya: Sheet Jala

- Ahar: Vegetarian diet.

### Raktapitta samprapti<sup>[3]</sup>

The consumption of Pitta-aggravating factors (Nidanas) initiates the vitiation of Pitta Dosha, especially its Drava and Ushna qualities.

↓

The aggravated Pitta enters and contaminates Rakta Dhatu, leading to Pitta-Rakta Dushti.

↓

Due to the excessive heat and liquidity of vitiated Pitta, the fluid components of the body (including Sneha and Lasika) are displaced from their respective sites and mix with the blood.

↓

This results in an abnormal increase in the volume and fluidity of Rakta Dhatu, producing heightened pressure within the blood channels (RaktavahaSrotas).

↓

The elevated pressure, combined with the corrosive nature of Pitta, causes weakening or rupture of the vascular channels (Sira Sada/Sira Bheda).

↓

Once the integrity of these channels is compromised, blood begins to flow outward through various bodily orifices (Nava Dwara) and through the skin, manifesting as petechiae, ecchymosis, and bleeding.

↓

This pathological process – characterized by Pitta-vitiated blood flowing in an abnormal direction – is understood as TiryakgataRaktapitta.

### Investigations

???

AQ4

#### Follow-up 1 (December 18, 2021)

- Continue above
- Add Hemoplan syrup and Clotoplan syrup, 1 tsp BD.

#### Follow-up 2 (January 18, 2022)

- Continue above
- Add Balarka Rasa 1 tab BD.

**AQ10** **Table 1:** CBC –(November 16, 2021)

Parameter	Observed value	Reference range	Interpretation
Hb	9.4 g/dL	11–15	↓Low
WBC	5600/cmm	4500–11000	Normal
Platelet count	<b>33,000/cmm</b>	150,000–450,000	Severely reduced
Peripheral smear	Reduced platelets, hypochromic microcytic anemia		

WBC: White blood cell, Hb: Hemoglobin, CBC: Complete blood count, Bold values indicate statistically significant improvement ( $p < 0.05$ )

**AQ10** **Table 2:** Repeat CBC (November 17, 2021 – midas diagnostic center)

Parameter	Result	Reference range	Parameter
Hb	11.6 g/dL	12–18	Hb
WBC	3300/cmm	4000–11000	WBC
Platelet count	<b>11,000/cmm</b>	150,000–450,000	Platelet count
Peripheral smear	Platelets reduced on smear		

CBC: Complete blood count, WBC: White blood cell, Hb: Hemoglobin, Bold values indicate statistically significant improvement ( $p < 0.05$ )

**Follow-up 3 (February 22, 2022)**

- Continue the same treatment
- Diet counseling emphasized.

**Diet and lifestyle recommendations**


- Avoid: Spicy foods, processed foods, citrus fruits, fried snacks, non-vegetarian items
- Include:
  - Green juice (spinach, papaya leaf, wheatgrass, amla, mint, durva grass)
  - Red juice (pomegranate, beetroot, carrot, apple, rhododendron).
- Encourage rest and a stress-free environment
- Lukewarm water for consumption.

**RESULTS AND FOLLOW-UPS**

???

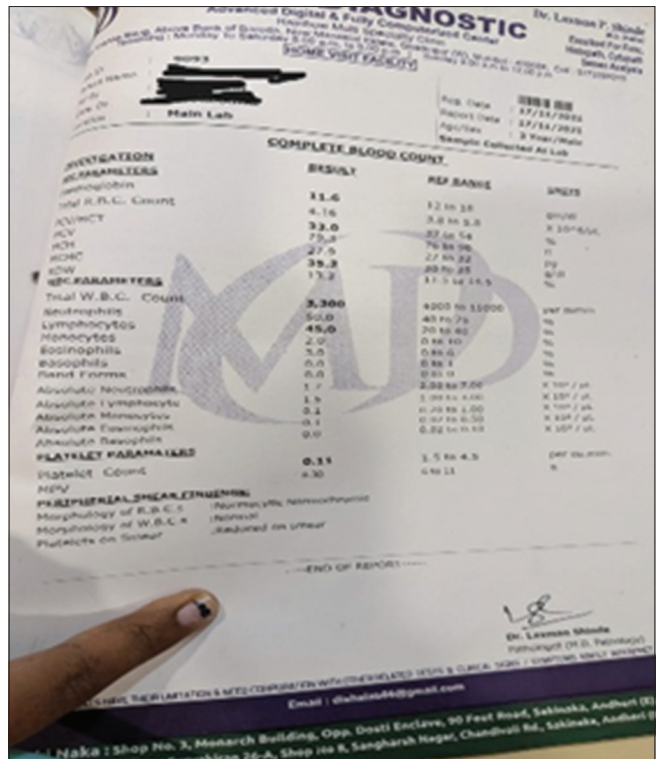
**Clinical improvement**

- 1<sup>st</sup> follow-up result after 4 weeks: Petechiae resolved, gum bleeding stopped, appetite and strength improved
- 2<sup>nd</sup> follow-up result after 8 weeks: Platelet count normalized to 1.98 lakh/cmm



**Figure 1:** Initial complete blood count (November 11, 2021) – Rashmeeta diagnostic center

**AQ9**



**Figure 2:** Complete blood count- November 17, 2021

**AQ9**

- 3<sup>rd</sup> follow-up result after 12 weeks: Platelets maintained at 2.29 lakh/cmm, no relapse.

The child showed significant clinical improvement within 4 weeks. Petechiae resolved completely, appetite improved, and energy levels increased. The platelet count, which was initially 11,000/cmm, increased to 1.98 lakh/cmm

**AQ10** **Table 3:** Treatment plan, November 17, 2021

Sr. No.	Medicine name	Form	Dose	Frequency	Anupana (Vehicle)	Duration	Remarks/Therapeutic use
1	SypPlateup	Syrup	1 tsf (≈5 mL)	BD (twice daily)	—	As advised	To improve platelet count, strengthen immunity, and enhance blood formation
2	Tab Kumar Kalyan Rasa	Tablet	1 tab	BD (twice daily)	With honey	As advised	<i>Rasayana</i> for child growth, strength, and immunity
3	Tab Suvarna Vasant Malti Rasa	Tablet	½ tab	BD (twice daily)	With honey	As advised	Immunomodulator; supports vitality and recovery
4	Arvindasava	Asava	1 tsf (≈5 mL)	BD (twice daily)	After meals	As advised	<i>Balya</i> (tonic); improves digestion, nourishment, and overall strength

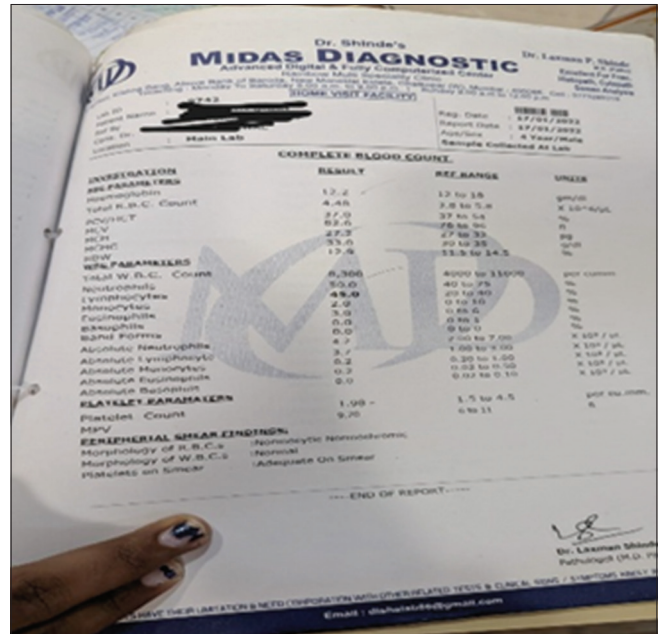
**AQ10** **Table 4:** Post-treatment CBC (January 17, 2022)

Parameter	Result	Reference range	Interpretation
Hb	12.2 g/dL	12–18	Normal
WBC	8300/cmm	4000–11000	Normal
Platelet count	<b>1.98 lakh/cmm</b>	1.5–4.5 lakh	Normalized
Smear	Adequate platelets		

CBC: Complete blood count, WBC: White blood cell, Hb: Hemoglobin

**AQ6,10** **Table 5:** Follow-up CBC (February 25, 2022)

Parameter	Result	Reference Range	Interpretation
Hb	12.1 g/dl	12–18	Normal
WBC	8600 /cmm	4000–11000	Normal
Platelet Count	<b>2.29 lakh /cmm</b>	1.5–4.5 lakh	Maintained
Smear	Adequate platelets		



**Figure 3:** Complete blood count- January 17, 2022

after 2 months of treatment and further stabilized at 2.29 lakh/cmm after 1 month of follow-up without relapse.

## DISCUSSION

ITP involves immune-mediated destruction of platelets and impaired megakaryocyte function.<sup>[5,6]</sup> Ayurveda explains such bleeding tendencies under *Raktapitta*, occurring due to *Pitta*-induced *Rakta Dushti* and *Srotovaigunya*.<sup>[3]</sup>

The Ayurvedic therapeutic approach in this case included:

- *Raktapitta Chikitsa* (Pitta-pacifying, Rakta-stabilizing measures)
- *Rasayana* therapy (immune modulation, tissue regeneration)
- *Raktaprasadana* (purification and rejuvenation of *Rakta Dhatu*).

Key medicaments, such as Giloy, Amla, Tulsi, Neem, and Papaya leaf<sup>[1,4]</sup> (in Plateup syrup) possess documented

immunomodulatory and hematopoietic properties. *Suvarna Vasant Malti Rasa* and *Kumar Kalyan Rasa* support immunity, enhance vitality, and stabilize the hematological system.

Dietary interventions supported restoration of *Agni*, reduced *Pitta*, and improved *Rakta Dhatu*.

The child achieved sustained remission without adverse effects, suggesting that Ayurveda can complement ITP management. However, the limitations of a single case must be acknowledged.

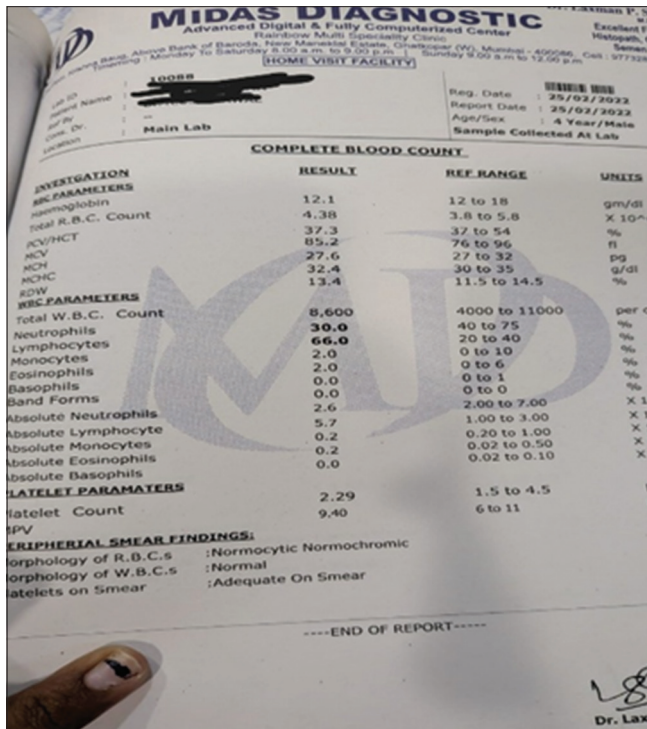
The patient was instructed to avoid processed food products, non-vegetarian food, spicy food, and *Citrus* fruits.

The clinical improvement observed in this case aligns with previous reports suggesting beneficial outcomes of Ayurvedic therapy in ITP.<sup>[4]</sup>

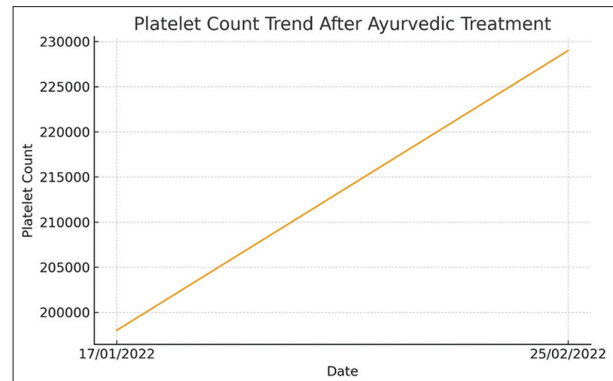
AQ10

**Table 6:** Rasapanchaka of ingredients in plateup syrup

No.	Ingredient	Botanical name	Rasa (taste)	Guna (qualities)	Veerya (potency)	Vipaka (post-digestive effect)	Dosha karma/Main action
1	<i>Carica papaya patra</i> (Papaya leaf)	<i>Carica papaya</i>	Tikta, Kashaya	Laghu, Ruksha	Ushna	Katu	Kapha-Pitta Shamaka; increases platelet count, Rakta vardhaka
2	Guduchi	<i>Tinospora cordifolia</i>	Tikta, Kashaya	Laghu, Snigdha	Ushna	Madhura	Tridosha Shamaka (especially Pitta Vata); Rasayana, immunomodulator
3	Amla	<i>Emblica officinalis</i>	Amla (dominant), Madhura, Kashaya	Laghu, Ruksha	Sheeta	Madhura	Tridosha Shamaka (esp. Pitta Shamaka); Rasayana, antioxidant
4	Tulsi	<i>Ocimum sanctum</i>	Katu, Tikta	Laghu, Ruksha	Ushna	Katu	Kapha-Vata Shamaka; immunomodulator, anti-inflammatory
5	Neem	<i>Azadirachta indica</i>	Tikta, Kashaya	Laghu, Ruksha	Sheeta	Katu	Pitta-Kapha Shamaka; Rakta-shodhaka (blood purifier), antimicrobial
6	Ashwagandha	<i>Withaniasomnifera</i>	Tikta, Madhura, Kashaya	Laghu, Snigdha	Ushna	Madhura	Vata-Kapha Shamaka; Balya, Rasayana
7	Punarnava	<i>Boerhaavia diffusa</i>	Tikta, Kashaya, Madhura	Laghu, Ruksha	Ushna	Madhura	Tridosha Shamaka; diuretic, hepatoprotective
8	Haridra (Turmeric)	<i>Curcuma longa</i>	Katu, Tikta	Laghu, Ruksha	Ushna	Katu	Kapha-Vata Shamaka; anti-inflammatory, Rakta-shodhaka



**Figure 4:** Complete blood count- February 25, 2022



**Figure 5:** Platelet count trend

## CONCLUSION

This case demonstrates that Ayurvedic management focusing on *Raktashodhana* and *Rasayana* can effectively manage ITP in children. Ayurveda may offer a safe, supportive therapeutic approach in pediatric hematological disorders. Larger controlled studies are needed for validation.

The therapy resulted in normalization of platelet count and sustained remission. Further clinical studies are

AQ9

AQ9

recommended to validate these findings and standardize the therapeutic protocol.

## PATIENT CONSENT

Written informed consent was obtained from the child's parents for publication of clinical details.

## FUNDING

No external funding was received for this case report.

## REFERENCES

1. Pandey GS. Bhavaprakasha Nighantu. Varanasi: Chaukhambha Bharati Academy; 2018.

2. Sharma P.V. Dravyaguna Vijnana. Varanasi: Chaukhambha Bharati Academy; 2013.
3. Agnivesha. Charaka Samhita (Chikitsa Sthana 7/10). Varanasi: Chaukhambha Sanskrit Sansthan; 2014.
4. Singh G, Gupta N. Ayurvedic management of ITP - a case report. J Ayurveda Integr Med 2020; 11:318-321.
5. Hoffman R. Hematology: Basic Principles and Practice. Netherlands: Elsevier; 2018.
6. Takahashi T, Yujiri T, Shinohara K, Inoue Y, Sato Y, Fujii Y, *et al.* Molecular mimicry by *Helicobacter pylori* CagA protein may be involved in the pathogenesis of *H. pylori*-associated chronic idiopathic thrombocytopenic purpura. Br J Haematol 2004;124:91-6.

**Source of Support:** Nil. **Conflicts of Interest:** None declared.

Author Queries???

AQ2: Kindly move the reference citation to the main text part (1, 5, 3)

AQ3: Kindly check the Headings levels throughout the manuscript

AQ4: Kindly provide text part

AQ6: Kindly provide editable table for Table 5

AQ7: Kindly cite reference citation 2 and also cite chronological order

AQ9: Kindly cite figures 1-5 in the text part

AQ10: Kindly cite tables 1-6 in the text part

AQ11: Kindly provide text part

Kindly mention the page no and line numbers for given corrections